Ministério da Saúde

Instituto Nacional de Câncer

Coordenação de Ensino

Curso de Aperfeiçoamento nos Moldes Fellow em Dermatologia em Oncologia

ANA PAULA MEDEIROS HORTÊNCIO

METÁSTASE CUTÂNEA PIGMENTADA DE CÂNCER DE MAMA

Rio de Janeiro

2025

ANA PAULA MEDEIROS HORTÊNCIO

METÁSTASE CUTÂNEA PIGMENTADA DE CÂNCER DE MAMA

Trabalho de Conclusão de Curso apresentado ao Instituto Nacional de Câncer como requisito parcial para a conclusão do Curso de Aperfeiçoamento nos Moldes Fellow em Dermatologia em Oncologia.

Orientador: Prof. Dr. Jorge Ricardo da Silva Machado

Revisão: Profª Drª Shirley Burburan

Rio de Janeiro

2025

CATALOGAÇÃO NA FONTE
INCA/COENS/SEITEC/NSIB
Kátia Simões CRB7/5952

H822m Hortêncio, Ana Paula Medeiros.
Metástase cutânea pigmentada de câncer de mama. / Ana Paula Medeiros. – Rio de Janeiro, 2025.
11f. il. color.

Trabalho de Conclusão de Curso (Aperfeiçoamento) - Instituto Nacional de Câncer, Programa de Aperfeiçoamento nos Moldes de Fellow em Dermatologia em Oncologia, Rio de Janeiro, 2025.

Orientador: Prof. Dr. Jorge Ricardo da Silva Machado.
Revisora: Profª Drª Shirley Burburan.

1. metástase neoplásica. 2. dermatoscopia. 3. neoplasias da mama. 4. diagnóstico precoce. 5. oncologia. I. Machado, Jorge Ricardo da Silva. (Orient.). II. Burburan, Shirley. (Rev). III. Instituto Nacional de Câncer. V. Título.

CDD 616.994 77

ANA PAULA MEDEIROS HORTÊNCIO

Metástase cutânea pigmentada de câncer de mama

Trabalho de Conclusão de Curso apresentado ao Instituto Nacional de Câncer como requisito parcial para a conclusão do Curso de Aperfeiçoamento nos Moldes Fellow em Dermatologia em Oncologia.

Aprovado em 6 de maio de 2025.

Examinadores:

Dr Jorge Ricardo Machado
Dermatologista
CRM 5252349-8

Orientador: Jorge Ricardo da Silva Machado

Dr. Dalval Lobão V. Filho
Médico - INCA
CRM 52 28280-6

Avaliador

Dra. Karla Strong
Dermatologista
CRM 5279836-3

Avaliado

Rio de Janeiro

2025

Dedico este trabalho aos meus colegas, que me apoiaram e incentivaram no decorrer do curso e participaram da elaboração deste trabalho.

AGRADECIMENTOS

Desejo expressar a minha profunda gratidão a Jorge Ricardo Machado, Stefano Trivelin, Gabriela Menegol e Georgia Neves que contribuíram para elaboração deste trabalho.

Pois a coragem cresce com a ocasião.

William Shakespeare

RESUMO

HORTÊNCIO, Ana Paula Medeiros. **Metástase cutânea pigmentada de câncer de mama**. Trabalho de Conclusão de Curso (Fellow em Dermatologia em Oncologia) — Instituto Nacional de Câncer (INCA), Rio de Janeiro, 2025.

O câncer de mama é o tumor maligno que mais frequentemente leva à morte de mulheres no Brasil e o que mais causa metástases cutâneas. As metástases cutâneas são definidas como tumores malignos que afetam a derme ou o tecido subcutâneo, mas não são contíguos ao tumor primário de origem. Metástases cutâneas de carcinoma de mama podem se apresentar com um amplo espectro de aspectos clínicos e histológicos, o que dificulta seu diagnóstico. A metástase cutânea pigmentada do câncer de mama pode ser difícil diferenciar do melanoma cutâneo, seu diagnóstico pode ser desafiador mas é de grande importância que seja realizado o quanto antes, uma vez que indica doença avançada e confere pior prognóstico ao paciente. A dermatoscopia, ferramenta clínica utilizada pelos dermatologistas, pode auxiliar no diagnóstico das metástases cutâneas pigmentadas. Existem poucos relatos na literatura de achados dermatoscópicos das metástases pigmentadas de câncer de mama. As descrições existentes relatam padrão de lesão melanocítica mimetizando melanoma cutâneo com presença de glóbulos, estrias, véu branco azulado, lesões assimétricas. O trabalho tem por objetivo descrever alguns achados dermatoscópicos de metástase cutânea pigmentada de câncer de mama através de um relato de caso. No caso apresentado são descritos dois padrões dermatoscópicos de metástases cutâneas pigmentadas de câncer de mama, uma com padrão homogêneo, outra com padrão reticuloglobular. Ambas apresentam assimetria de cor e estruturas, podem ser observados em lesões melanocíticas e fazem diagnóstico diferencial com melanoma. Para o diagnóstico correto é necessária análise histopatológica. O estudo imuno-histoquímico pode ser necessário para diferenciação etiológica da lesão.

Palavras-chave: metástases; dermatoscopia; câncer de mama; diagnóstico precoce; oncologia.

ABSTRACT

HORTÊNCIO, Ana Paula Medeiros. **Pigmented Cutaneous Metastasis of Breast Cancer.** Final paper (Fellowship in Oncological Dermatology) — Brazilian National Cancer Institute (INCA), Rio de Janeiro, 2025.

Breast cancer is the malignant tumor that most frequently leads to death among women in Brazil and the one that causes the most cutaneous metastases. Cutaneous metastases are defined as malignant tumors that affect the dermis or subcutaneous tissue, but are not contiguous with the primary tumor of origin. Cutaneous metastases from breast carcinoma can present with a wide spectrum of clinical and histological aspects, which makes their diagnosis difficult. Pigmented cutaneous metastases from breast cancer can be difficult to differentiate from cutaneous melanoma. Their diagnosis can be challenging, but it is of great importance that it be performed as soon as possible, since it indicates advanced disease and confers a worse prognosis for the patient. Dermoscopy, a clinical tool used by dermatologists, can aid in the diagnosis of pigmented cutaneous metastases. There are few reports in the literature of dermoscopic findings of pigmented metastases from breast cancer. The existing descriptions report a melanocytic lesion pattern mimicking cutaneous melanoma with the presence of globules, striae, bluish-white veil, and asymmetric lesions. The aim of this study is to describe some dermoscopic findings of pigmented cutaneous metastasis of breast cancer through a case report. In the case presented, two dermoscopic patterns of pigmented cutaneous metastases of breast cancer are described, one with a homogeneous pattern and the other with a reticuloglobular pattern. Both present asymmetry of color and structures, can be observed in melanocytic lesions, and are differentially diagnosed with melanoma. Histopathological analysis is necessary for correct diagnosis. Immunohistochemical study may be necessary for etiological differentiation of the lesion.

Keywords: metastases; dermoscopy; breast cancer; early diagnosis; oncology.

PIGMENTED CUTANEOUS METASTASIS OF BREAST CANCER

Medeiros Hortêncio, Ana Paula | Machado, Jorge | França, Natália | De Avelar Alchorne Trivelin, Stefano |Neves Barros de Almada Justino, Georgia | Menegol Bassani, Gabriela
Brazilian National Cancer Institute (INCA), Rio de Janeiro – RJ, Brazil
Author e-mail: anapaulam.hortencio@gmail.com

INTRODUCTION

Breast cancer is the malignant tumor that most frequently kills women in the world and is also the leading cause of cutaneous metastases. Cutaneous metastases are defined as malignant tumors affecting the dermis or subcutaneous tissue but not contiguous to the primary tumor of origin. Cutaneous metastases from breast carcinoma can present with a wide spectrum of clinical and histological aspects, making them difficult to diagnose.

CASE PRESENTATION

A 44-year-old female diagnosed in 2019 with invasive ductal carcinoma in the right breast and ductal carcinoma in situ in the left breast, treated with radical mastectomy, radiotherapy, and chemotherapy, progressing to bone and liver disease. On examination, erythematous plaques with areas of hyperpigmentation, hardened, with an orange peel-like surface extending from the right pectoral region to the right scapular and mid-back were observed. Dermatoscopy of the pigmented lesion in the right pectoral region demonstrated an expanded reticuloglobular pattern with asymmetric hyperpigmented globules in two axes (Figure 1). A lesion on the mid-back with overlying blackened plaque, dermatoscopy showed a homogeneous pattern with color asymmetry (blue, black, and brown) (Figure 2). Histopathological examination of the lesions revealed metastatic carcinoma to the skin, consistent with the primary site of the breast. The patient died 3 months later.

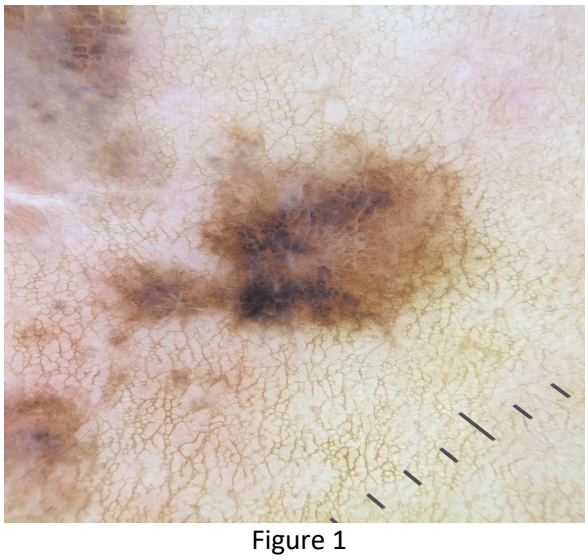

Figure 1

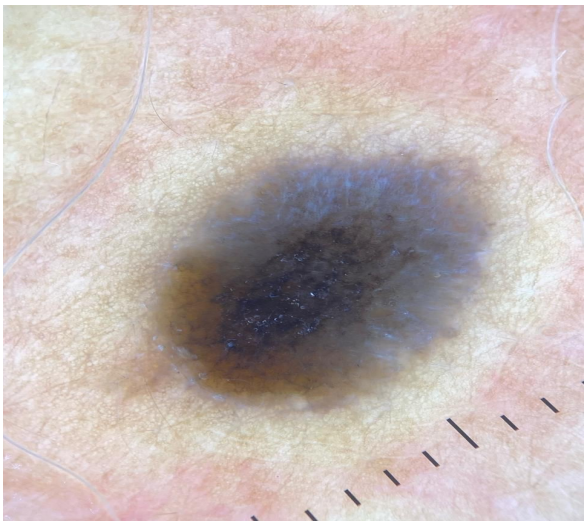

Figure 2

DISCUSSION

Cutaneous metastases are a rare finding in clinical practice, with a prevalence ranging from 0.7% to 9% of patients with internal tumors. Breast carcinoma is the most common cause of cutaneous metastases in women, comprising approximately 70% of all cutaneous metastases. The most frequent location is on the chest and abdomen near the mastectomy scar area. Pigmented cutaneous metastasis is a rare cutaneous manifestation of underlying mammary malignancy with a wide spectrum of clinical aspects and can be difficult to differentiate from cutaneous melanoma. There are few reports in the literature on dermoscopic findings of pigmented metastases from breast cancer. Existing descriptions report a pattern of melanocytic lesion mimicking cutaneous melanoma with the presence of globules, streaks, bluish-white veil, and asymmetric lesions. The presented case describes two dermoscopic patterns of pigmented cutaneous metastases from breast cancer, one with a homogeneous pattern and the other with a reticuloglobular pattern. Both exhibit color and structural asymmetry, may be observed in melanocytic lesions, and warrant differential diagnosis with melanoma. Histopathological analysis is necessary for correct diagnosis. Immunohistochemical study may be required for etiological differentiation of the lesion. Thus, the diagnosis of pigmented metastases may be challenging but it is crucial to perform it as early as possible, as it indicates advanced disease and confers a worse prognosis to the patient. Knowledge of the pigmented presentation and most frequent location are clues that may raise diagnostic suspicion. Dermatoscopy can be a useful tool, although there are still few data on dermoscopic findings of these lesions.

CONFLICTS OF INTEREST

None declared.

BIBLIOGRAPHY

1) Yalici-Armagan, B., Demircan, C., & Elcin, G. (2019). Melanomalike pigmented cutaneous metastasis of breast carcinoma. International wound journal, 16(6), 1570-1571. https://doi.org/ 10.1111/iwj.13181
2) Ubilos, N., Vola, M., Mazzei, M. E., & Magliano, J. (2016). Pigmented Cutaneous Metastasis of Breast Carcinoma Mimicking a Melanoma. Actas dermo-sifiliograficas, 107(8), 699-701.https:// doi.org/10.1016/j.ad.2016.04.007
3) Chernoff, K. A., Marghoob, A. A., Lacouture, M. E., Deng, L., Busam, K. J., & Myskowski, P. L. (2014). Dermoscopic findings in cutaneous metastases. JAMA dermatology, 150(4), 429-433. https://doi.org/10.1001/jamadermatol.2013.8502

6th World Congress of
DERMOSCOPY 2024
BUENOS AIRES, ARGENTINA / 16 - 19 OCTOBER 2024
"WCD2024 Together Again"

This certifies that

Medeiros Hortêncio, Ana Paula; Machado, Jorge; França, Natália; De Avelar Alchorne Trivelin, Stefano; Neves Barros De Almada Justino, Georgia; Menegol Bassani, Gabriela

have presented the Abstract entitled

"PIGMENTED CUTANEOUS METASTASIS OF BREAST CANCER"

as ePoster.

Buenos Aires, October 19, 2024

Horacio Cabo	Gabriel Salerni	Aimilios Lallas	Caterina Longo
President of the WCD2024	**General Secretary WCD2024**	**President of the IDS**	**General Secretary IDS**