



Ministério da Saúde
Instituto Nacional de Câncer José Alencar Gomes da Silva
Coordenação de Ensino
Programa de Residência Médica em Radiologia e Diagnóstico por Imagem

CAROLINA ÁVILA DE ALMEIDA

**CHARACTERIZATION OF A GLOMUS TUMOR USING 33-MHZ ULTRASOUND
AND SUPERB MICROVASCULAR IMAGING**

Rio de Janeiro
2021

CAROLINA ÁVILA DE ALMEIDA

**CHARACTERIZATION OF A GLOMUS TUMOR USING 33-MHZ
ULTRASOUND AND SUPERB MICROVASCULAR IMAGING**

Trabalho de Conclusão de Curso apresentado ao Instituto Nacional de Câncer José Alencar Gomes da Silva como requisito parcial para a conclusão do Programa de Residência Médica em Radiologia e Diagnóstico por Imagem.

Orientadora: Prof. Dra. Clarissa Canella Moraes do Carmo

**Rio de Janeiro
2021**

Characterization of a glomus tumor using 33-MHz ultrasound and superb microvascular imaging

We read with great interest the recently published article by Sechi et al,¹ which describes the ultrasound features of subungual glomus tumors and squamous cell carcinomas. We would like to share our experience with the characterization of a glomus tumor using a 33-MHz probe and superb microvascular imaging (SMI).

A 56-year-old man presented at our dermatology service with a 7-year history of pain in the nail area of the right second finger. The patient reported that the pain worsened, with paroxysmal behavior, when he touched cold surfaces, but that he was unable to precisely locate the point of pain. A radiologist with 15 years of experience performed a high-frequency ultrasound examination using the Aplio i800 device (Canon Medical Systems Corporation, Tokyo, Japan) with a 33-MHz transducer. Ultrasound showed a hypoechoic lesion with well-defined margins that was causing bone remodeling in the adjacent distal phalanx (Figure 1). Power Doppler imaging (PDI) showed intense vascularization, and color and monochrome SMI enabled the identification of a large tangle of vessels and the stalk sign (Figure 2). The diagnosis of glomus tumor was made and confirmed by histopathological analysis after surgical excision of the mass.

Glomus tumors originate from glomus bodies, which are neuro-myoeipithelial anastomoses responsible for the control of temperature and blood pressure via the regulation of peripheral blood flow.² They are benign and rare lesions, accounting for 1-5% of all soft-tissue tumors originating in the hands.³ They have a slight female predisposition,⁴ and on average, they are diagnosed in the fourth

decade of life.⁵ Symptoms of glomus tumors include the classic triad of hypersensitivity to cold, paroxysmal pain, and precise pain location, although approximately 25% of patients do not have all of these symptoms.⁶

Glomus tumors appear on high-frequency ultrasound as small, solid hypoechoic lesions with well-defined margins, and PDI or color Doppler imaging (CDI) demonstrates intense vascularization.^{7,8} The stalk sign represents intense vascular flow connecting the lesion to the adjacent tissue and is seen on ultrasound in approximately 60% of glomus tumors.⁹

The imaging modalities used most commonly for the evaluation of the nail apparatus are magnetic resonance imaging (MRI)

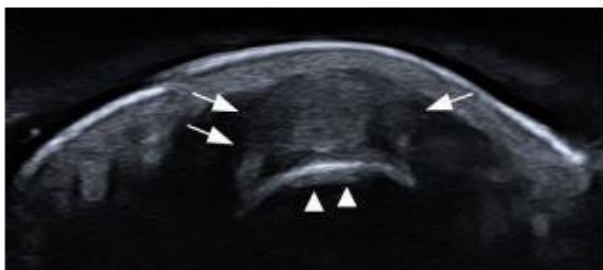


FIGURE 1 Axial image of the nail region of the right second finger, obtained using high-frequency B-mode ultrasound a 33-MHz transducer, showing a hypoechoic lesion with well-defined margins (white arrows) and minor bone remodeling of the adjacent distal phalanx (arrowheads)

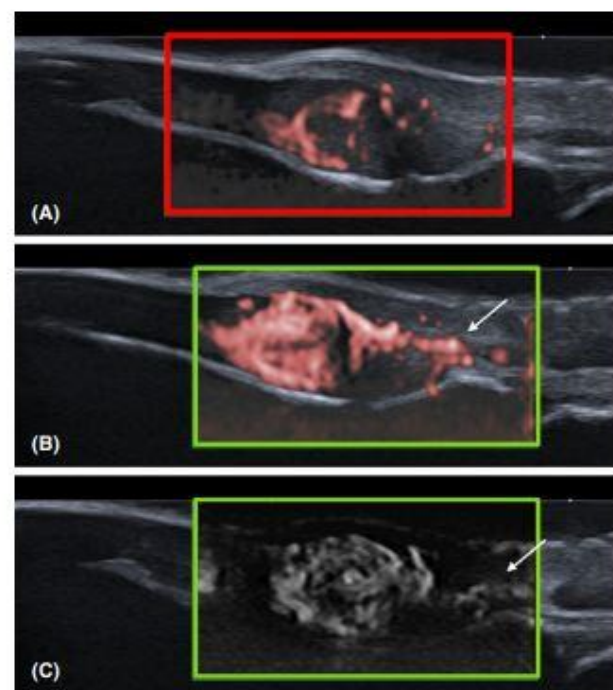


FIGURE 2 Ultrasound images of the subungual glomus tumor, obtained with a 33-MHz probe. (A) Power Doppler image showing intense vascularization of the lesion. Color (B) and monochrome (C) superb microvascular images showing the high concentration of blood vessels and the presence of the stalk sign (white arrows)

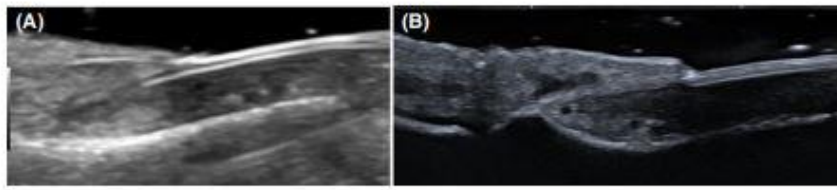


FIGURE 3 High-frequency ultrasound images of a normal nail obtained with 18-MHz (A) and 33-MHz (B) probes. Note the higher resolution and clear difference in the echogenicity of the skin layers in B

and high-frequency ultrasound; MRI assessment of nails, however, requires specialized equipment and is expensive. High-frequency ultrasound, performed using probes with frequencies exceeding 15 MHz, is the imaging modality of choice for this type of assessment because it is widely available and less expensive.¹⁰

Most ultrasound evaluations of the subungual region have been performed using transducers with frequencies ranging from 15 to 18 MHz.^{1,11,12} Wave penetration decreases, and image definition increases with increasing ultrasound frequency.¹³ In the case presented here, the use of a 33-MHz transducer provided better surface resolution than achieved with lower wave frequencies, such as 18 MHz (Figure 3).

The ultrasound evaluation of subungual lesions with PDI or CDI is important for the characterization of vascular lesions and inflammatory activity.¹⁴ However, the utility of PDI and CDI for the evaluation of small structures, such as vessels with diameters of less than 0.1 mm, is limited.¹⁵ In addition, typically used Doppler techniques fail to differentiate movement artifacts from blood flow; to address this problem, a filter can be added to eliminate signals from slow blood flow.¹⁵

SMI is a new technology incorporated into ultrasound.¹⁶ It allows the evaluation of low-speed blood flow without the use of contrast, making it safer and more economical than contrast-enhanced ultrasonography,¹⁷ and it enables better detection and morphological characterization of microvessels than PDI or CDI.¹⁸ SMI uses an adaptive algorithm that removes clutter artifacts while maintaining sensitivity to low-speed blood flow without the interference of movement artifacts from nearby structures.^{19,20} SMI can be performed in color and monochrome; color SMI provides the information seen with B-mode ultrasound, with color added to the vessels (Figure 2B), and monochrome SMI provides better sensitivity through a focus on vascularization with the removal of other information (Figure 2C).¹⁶

The case presented here demonstrates that SMI aids the detection of glomus tumors, most of which have millimetric dimensions, and allows better visualization than does PDI, as these structures have high concentrations of microvessels.⁴

Our experience shows that the use of SMI with high-frequency ultrasound is convenient because it allows better evaluation of slow blood flow than do commonly used methods such as PDI and CDI.^{17,18} After the article by Kaya İslamoğlu et al,²¹ this work is the second to describe the use of SMI in dermatology. Additional studies of such applications of SMI and high-frequency ultrasound are

required to elucidate the use of this new technology to aid diagnostic skin assessment.

Carolina Ávila de Almeida¹ 

Simone Guarçoni²

Andreia Leverone³

Robertha Nakamura³

Edson Marchiori⁴

Clarissa Canella^{2,5}

¹Instituto Nacional de Câncer - INCA, Rio de Janeiro, Brazil

²Alta Excelência Diagnóstica - DASA, Rio de Janeiro, Brazil

³Instituto de Dermatologia Professor Rubem David Azulay, Santa Casa da Misericórdia do Rio de Janeiro, Rio de Janeiro, Brazil

⁴Universidade Federal do Rio de Janeiro, Rio de Janeiro, Brazil

⁵Universidade Federal Fluminense, Rio de Janeiro, Brazil

Correspondence

Carolina Ávila de Almeida, Serviço de Radiologia e Diagnóstico por Imagem, Instituto Nacional de Câncer - INCA, Praça da Cruz Vermelha, nº 23, 3º floor, 20230-130, Rio de Janeiro, Brazil.
Email: carolinaaviladealmeida@gmail.com

ORCID

Carolina Ávila de Almeida  <https://orcid.org/0000-0001-7084-5904>

REFERENCES

- Sechi A, Alessandrini A, Patrizi A, et al. Ultrasound features of the subungual glomus tumor and squamous cell carcinomas. *Ski Res Technol*. 2020;1-9. <https://doi.org/10.1111/srt.12888>
- De FF, Luis NM, Ramos A, Correia AR, De OM, Palma L. *Tumor glômico subungueal*. 2012;20:249-254.
- Fabro M, Fabro SRM, Klitzke BB, de Araújo GL, Machado CA. Glomus tumor: revitalizing concepts. *Radiol Bras*. 2015;48:269-270.
- Sprinkle RLB, Sanguenza OP, Schwartz GA. Glomus Tumor of the Toe. *J Am Podiatr Med Assoc*. 2017;107:257-260.
- Montandon C, da Costa J, Montandon LA, et al. Subungual glomus tumors: imaging findings. *Radiol Bras*. 2009;42:371-374.
- Mundada P, Becker M, Lenoir V, et al. High resolution MRI of nail tumors and tumor-like conditions. *Eur J Radiol*. 2019;112:93-105.
- Lee DY, Hwang SC, Jeong ST, et al. The value of diagnostic ultrasonography in the assessment of a glomus tumor of the subcutaneous layer of the forearm mimicking a hemangioma: A case report. *J Med Case Rep*. 2015;9:1-6.

8. Gómez-Sánchez ME, Alfageme-Roldán F, Roustán-Gullón G, Segurado-Rodríguez MA. The usefulness of ultrasound imaging in digital and extradigital glomus tumors. *Actas Dermosifiliogr*. 2014;105:e45-e49.
9. Park HJ, Jeon YH, Kim SS, et al. Gray-scale and color Doppler sonographic appearances of nonsubungual soft-tissue glomus tumors. *J Clin Ultrasound*. 2011;39:305-309.
10. Wortsman X, Jemec GBE. Ultrasound Imaging of Nails. *Dermatol Clin*. 2006;24:323-328.
11. Idolazzi L, Zabotti A, Fassio A, et al. The ultrasonographic study of the nail reveals differences in patients affected by inflammatory and degenerative conditions. *Clin Rheumatol*. 2019;38:913-920.
12. Aluja Jaramillo F, Quiasúa Mejía DC, Martínez Ordúz HM, González AC. Nail unit ultrasound: a complete guide of the nail diseases. *J Ultrasound*. 2017;20:181-192.
13. de Barcaui EO, Carvalho ACP, Lopes FPPL, Piñeiro-Maceira J, Barcaui CB. High frequency ultrasound with color Doppler in dermatology. *An Bras Dermatol*. 2016;91:262-273.
14. Wortsman X. Common applications of dermatologic. *J Ultrasound Med*. 2012;31:97-111.
15. Jiang Z, Huang Y, Shen H, Liu X. Clinical Applications of Superb Microvascular Imaging in the Liver, Breast, Thyroid, Skeletal Muscle, and Carotid Plaques. *J Ultrasound Med*. 2019;38:2811-2820.
16. Ayaz E, Aslan A, İnan I, Yıkılmaz A. Evaluation of Ovarian Vascularity in Children by Using the "Superb Microvascular Imaging" Ultrasound Technique in Comparison With Conventional Doppler Ultrasound Techniques. *J Ultrasound Med*. 2019;38:2751-2760.
17. Lu R, Meng Y, Zhang Y, et al. Superb microvascular imaging (SMI) compared with conventional ultrasound for evaluating thyroid nodules. *BMC Med Imaging*. 2017;17:65.
18. Park AY, Kwon M, Woo OH, et al. A Prospective Study on the Value of Ultrasound Microflow Assessment to Distinguish Malignant from Benign Solid Breast Masses: Association between Ultrasound Parameters and Histologic Microvessel Densities. *Korean J Radiol*. 2019;20:759.
19. Gabriel M, Tomczak J, Snoch-Ziótkiewicz M, Dzieciuchowicz Ł, Strauss E, Oszkinis G. Comparison of Superb Micro-Vascular Ultrasound Imaging (SMI) and Contrast-Enhanced Ultrasound (CEUS) for Detection of Endoleaks After Endovascular Aneurysm Repair (EVAR). *Am J Case Rep*. 2016;17:43-46.
20. Fu Z, Zhang J, Lu Y, et al. Clinical Applications of Superb Microvascular Imaging in the Superficial Tissues and Organs: A Systematic Review. *Academic Radiology*. 2020;1-10. <https://doi.org/10.1016/j.acra.2020.03.032>
21. Kaya İslamoğlu ZG, Uysal E. A preliminary study on ultrasound techniques applied to cicatricial alopecia. *Ski Res Technol*. 2019;25(6):810-814. <https://doi.org/10.1111/srt.12725>